

# Alveolar Bone Expansion for Implant Placement in Compromised Aesthetic Zone – Case Series

JUMSHAD B. MOHAMED<sup>1</sup>, MD NAZISH ALAM<sup>2</sup>, GURUDEEP SINGH<sup>3</sup>, S. C. CHANDRASEKARAN<sup>4</sup>

## ABSTRACT

Implant placement and restoration of compromised alveolar ridges in the aesthetic zone has always been a challenge to the oral implantologists. The use of bone expanders and bone condensers without the use of traditional drilling sequences in this scenario is becoming popular because of its predictable results. Xenograft along with Platelet-rich fibrin (PRF) used as scaffold also provides growth factors to accelerate both soft and hard tissue healing as well as regeneration. The paper highlights this combined approach in the placement of implants in compromised alveolar ridges with good results. All implants were successfully restored and followed up for one year.

**Keywords:** Osteotomes, Platelet-Rich Fibrin, Dental Implants

## CASE REPORTS

**Case 1:** A 24-year-old male patient presented to the Department Of Periodontics and Implant Dentistry for management of partially edentulous area in the maxillary anterior region in relation to tooth no.12 [Table/Fig-1a]. After clinical and radiographic evaluation the patient was given the option of dental implant versus crown and bridge, the patient opted for the former. After induction of local anaesthesia, a paracrestal incision was given using Bard Parker scalpel #15 and a full thickness flap was elevated. Due to deficient bone, osteotomy was initiated using a sharp pilot D-shaped expander followed by condensation of the osteotomy site using bone condensers [Table/Fig-1b]. Following the osteotomy dental implant<sup>s</sup> of size 3.5x 11.5 mm was placed [Table/Fig-1c] achieving primary stability. On the facial aspect xenograft\* and PRF [Table/Fig-1d] was placed for augmentation of deficient region and sutured using 3-0 silk sutures. Post-operative instructions and medications were prescribed for five days and the patient was reviewed after 24 hours. Every month clinical follow-up was done along with intraoral periapical radiographs. The implant was perfectly osseointegrated within the confines of the bone with in a period of 3 months following which second stage surgery was performed for healing abutment placement. Final prosthesis was placed and reviewed clinically and with radiographic evaluation every 3 months for 1-year period [Table/Fig-1e, 1f]. Excellent aesthetics was achieved.

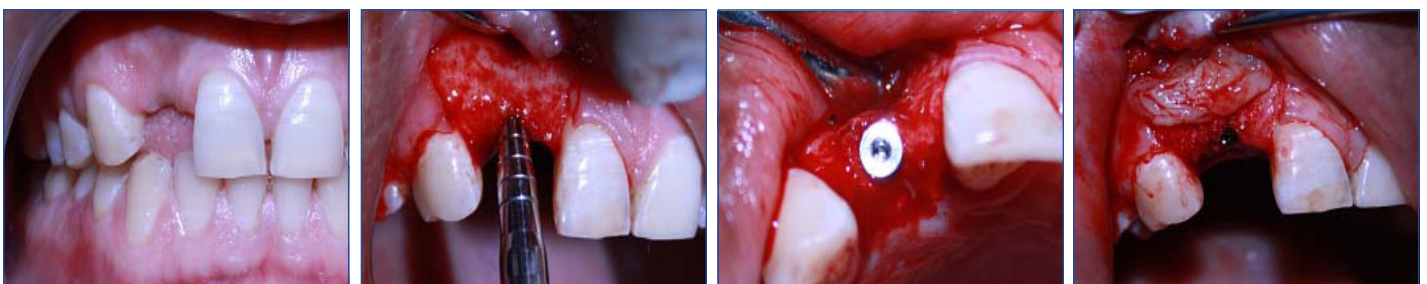**Case 2:** A 37-year-old male patient presented to the Department Of Periodontics & Implant Dentistry for management of partially edentulous area in the maxillary anterior region in relation to tooth no.12. After clinical and radiographic evaluation the patient was given the option of dental implant versus crown & bridge, the patient opted for the former. Same surgical protocol followed as the first case and dental implant<sup>s</sup> size 3.5x13 mm [Table/Fig-2a, 2b] was placed followed by xenograft\* and PRF. The implant was perfectly osseointegrated within the confines of the bone with in a period

of 3 months following which second stage surgery was performed for healing abutment placement. Final prosthesis was placed and reviewed clinically and with radiographic evaluation [Table/Fig-2c] every 3 months for 1- year period.

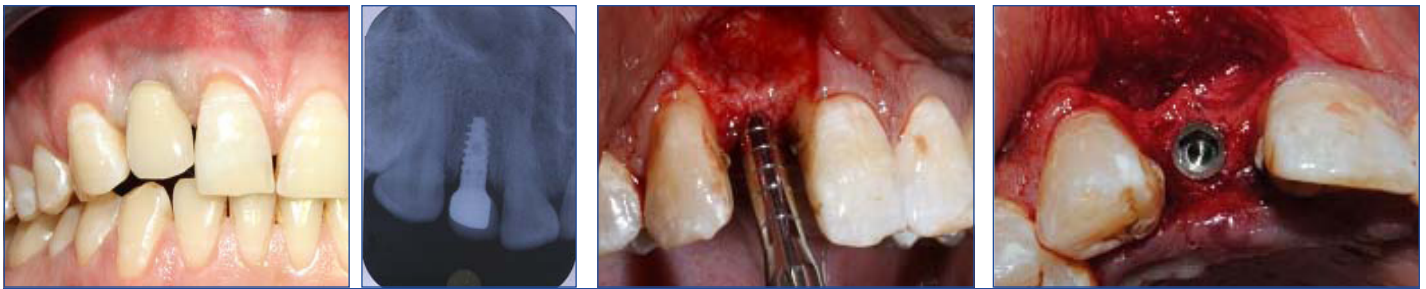
**Case 3:** A 26-year-old male patient presented to the Department Of Periodontics & Implant Dentistry for management of partially edentulous area in maxillary anterior region in relation to tooth no.11. After clinical and radiographic evaluation the patient chose placement of dental implant. A dental implant<sup>s</sup> size 3.5x13 mm was placed [Table/Fig-3a, 3b] followed by xenograft\* and PRF. The implant was perfectly osseointegrated in 3 months' time when second stage surgery was performed for healing abutment placement. Final prosthesis was placed and reviewed clinically and with radiographic evaluation [Table/Fig-3c] every 3 months for 1- year period.

## DISCUSSION

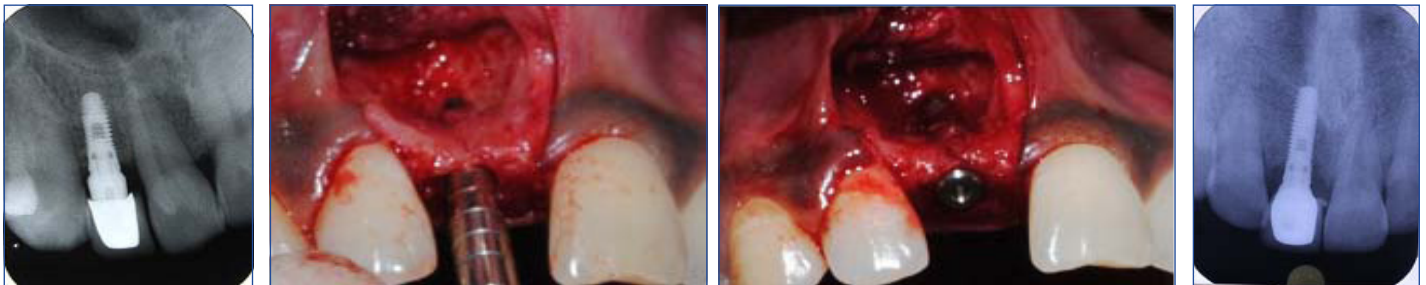The technique discussed in this article have been derived from a combination of techniques suggested by Hom Lay Wang and Carl Misch [1] where their aim was augmentation of deficient alveolar ridge and correction of osseous defects around dental implants along with Tatum's expansion techniques. Elimination of the drilling sequence prevents excessive bone loss and wash out of growth factors which helps in regeneration. Abstaining from drilling also prevents heat generation thereby avoiding bone necrosis and also aid in decreasing the healing duration of the site. PRF is a matrix of autologous fibrin in which are embedded a large quantity of platelet and leukocyte cytokines during centrifugation [2,3]. The presence of cytokines within the fibrin mesh allows for their progressive release over time period of 7-11 days which is the life span of platelet following which the network of fibrin disintegrates [4]. The PRF membrane acts like a fibrin bandage [5], which significantly serves as a matrix to accelerate the healing of the wound edges and surfaces [6]. The PRF provides post-operative protection to



**[Table/Fig-1a]:** Partially edentulous ridge **[Table/Fig-1b]:** Condensation of prepared osteotomy **[Table/Fig-1c]:** Dental implant placement **[Table/Fig-1d]:** Platelet-rich fibrin placed over Xenograft



**[Table/Fig-1e]:** Prosthetic rehabilitation. **[Table/Fig-1f]:** Radiograph **[Table/Fig-2a]:** Osteotomy site condensation **[Table/Fig-2b]:** Dental implant placement



**[Table/Fig-2c]:** Radiograph. **[Table/Fig-3a]:** Osteotomy site condensation **[Table/Fig-3b]:** Dental implant placement. **[Table/Fig-3c]:** Radiograph

the surgical site and also helps to accelerate the integration and remodelling of the grafted biomaterial [3,7]. The fibrin clot plays an important mechanical role, with the PRF membrane maintaining and protecting the grafted biomaterials and PRF fragments serving as biological connectors between bone particles [8,9]. The integration of this fibrin network into the regenerative site facilitates cellular migration, particularly for endothelial cells necessary for the neo-angiogenesis [2], vascularisation, and survival of the graft. The platelet cytokines (PDGF, TGF, IGF-1) are gradually released as the fibrin matrix is resorbed, thus creating a perpetual process of healing [10]. The presence of leukocytes and cytokines in the fibrin network can play a significant role in the self regulation of inflammatory and infectious phenomenon within the grafted material [11]. The clinical application of PRF helps in the integration and remodelling of both soft tissues as well as hard tissues. A major disadvantage could be the shorter duration of action of the fibrin matrix, which is about 7-10 days which signifies the life span of the platelets.

## CONCLUSION

With ever increasing patient acceptance and demand for implant retained prosthesis, Implantologists very often face the scenario of deficient and compromised anterior ridges in majority of cases where extensive ridge augmentation followed by implant placement is advocated. This involves a lot of time and expense as well as increased number of clinical visits. Promising results along with optimal aesthetics have been achieved by this technique wherein implants are placed followed by guided bone regeneration (GBR) with bone graft and PRF in a single visit. This tremendously reduces the time as well as the expenditure involved. We would advocate this technique as an alternative to augmentation by block bone grafts or GBR involving the use of expensive membranes; though further clinical trials comparing with other bone augmentation techniques are recommended.

\$ Touareg™ RP Adin Implant

\* Bio-Oss®

## REFERENCES

- [1] Wang HL, Misch C, Neiva RF. "Sandwich" bone augmentation technique: rationale and report of pilot cases. *Int J Periodontics Restorative Dent.* 2004 Jun;24(3):232-45
- [2] Dohan DM, Choukroun J, Diss A, Dohan SL, Dohan AJ, Mouhyi J, Gogly B. Platelet-rich fibrin (PRF): a second-generation platelet concentrate. Part I: technological concepts and evolution. *Oral Surg Oral Med Oral Pathol Oral Radiol Endod.* 2006; 101:e37-44.
- [3] Choukroun J, Adda F, Schoeffler C, Vervelle A. Une opportunité en parodontologie: le PRF. *Implantodontie.* 2001; 42:55-62.
- [4] Simonpieri A, Del Corso M, Sammartino G, Dohan Ehrenfest DM. The relevance of Choukroun's platelet-rich fibrin and metronidazole during complex maxillary rehabilitations using bone allograft. Part I: A new grafting protocol. *Implant Dent.* 2009; 18:102-11.
- [5] Vence BS, Mandelaris GA, Forbes DP. Management of dentoalveolar ridge defects for implant site development: An interdisciplinary approach. *Compend Cont Ed Dent.* 2009; 30(5):250-62.
- [6] Gabling VLW, Açil Y, Springer IN, Hubert N, Wiltfang J. Platelet-rich Plasma and Platelet-rich fibrin in human cell culture. *Oral Surg Oral Med Oral Pathol Oral Radiol Endod.* 2009; 108:48-55.
- [7] Dohan DM, Choukroun J, Diss A, Dohan SL, Dohan AJ, Mouhyi J, Gogly B. Platelet-rich fibrin (PRF): a second-generation platelet concentrate. Part II: platelet-related biologic features. *Oral Surg Oral Med Oral Pathol Oral Radiol Endod.* 2006; 101:e45-50.
- [8] Michael Toffler, Nicholas Toscano, Dan Holtzclaw, Marco Del Corso, David Dohan. Ehrenfest, Introducing Choukroun's Platelet Rich Fibrin (PRF) to the reconstructive surgery milieu. *The Journal of Implant & Advanced Clinical Dentistry.* 2009; 1(6):21-32
- [9] Simonpieri A, Del Corso M, Sammartino G, Dohan Ehrenfest DM. The relevance of Choukroun's platelet-rich fibrin and metronidazole during complex maxillary rehabilitations using bone allograft. Part II. Implant surgery, prosthodontics, and survival. *Implant Dent.* 2009; 18:220-29.
- [10] Mazar Z, Peleg M, Garg AK, Luboshitz J. Platelet-rich plasma for bone graft enhancement in sinus floor augmentation with simultaneous implant placement: patient series study. *Implant Dent.* 2004; 13:65-72.
- [11] Froum SJ, Wallace SS, Tarnow DP, Cho SC. Effect of platelet-rich plasma on bone growth and osseointegration in human maxillary sinus grafts: Three bilateral case reports. *Int J Periodontics Restorative Dent.* 2002; 22:45-53.

### PARTICULARS OF CONTRIBUTORS:

1. Assistant Professor, Department of Periodontics and Implant Dentistry, Sree Balaji Dental College & Hospital, Chennai, Tamil Nadu, India.
2. Senior Lecturer, Department of Periodontics and Implant Dentistry, Sree Balaji Dental College & Hospital, Chennai, Tamil Nadu, India.
3. Professor, Department of Periodontics and Implant Dentistry, Sree Balaji Dental College & Hospital, Chennai, Tamil Nadu, India.
4. Professor & HOD, Department of Periodontics and Implant Dentistry, Sree Balaji Dental College & Hospital, Chennai, Tamil Nadu, India.

### NAME, ADDRESS, E-MAIL ID OF THE CORRESPONDING AUTHOR:

Dr. Jumshad B. Mohamed,  
Assistant Professor, Department of Periodontics & Implant Dentistry, Sree Balaji Dental College & Hospital,  
Chennai - 600100 Tamil Nadu, India.  
Phone: +919884325366, E-mail: Jumshad77@gmail.com

**FINANCIAL OR OTHER COMPETING INTERESTS:** None.

Date of Submission: **Nov 24, 2012**  
Date of Peer Review: **Jun 18, 2013**  
Date of Acceptance: **Dec 19, 2013**  
Date of Publishing: **Feb 03, 2014**